

PHILIPS

Ultrasound

Clinical case study

eL18-4 PureWave linear array transducer

Category

Thyroid, Head and Neck, and Lymph Node Assessment

Authors

Dr. Andrew McQueen, Consultant Radiologist

Dr. Ben Stenberg, Consultant Sonographer

Dr. Andrew McNeill, Consultant Radiologist

Radiology, Freeman Hospital, Newcastle upon Tyne NHS Hospitals Trust, United Kingdom

The eL18-4 PureWave linear array in the detection of pharyngeal space neck pathology

Overview

Diagnostic ultrasound is the first-line investigation for neck masses, but has not previously been widely used to detect pathology of the pharyngeal space due to limited penetration of deeper tissue while maintaining diagnostic resolution.¹

Patient history

A 65-year-old male presented with a three-month history of left upper neck swelling and throat discomfort. Neck ultrasound performed in the referring hospital revealed a localized abnormality of the submandibular salivary gland, potentially representing a salivary neoplasm. Following non-diagnostic fine needle aspiration cytology sampling, the patient attended the regional head and neck center for specialist ultrasound assessment and ultrasound-guided core biopsy.

Protocol

The external ultrasound was performed using a Phillips iU22 L12-5 linear array with small parts standard pre-set, resolution mode, and 3.0 cm overall depth (bottom, left). Localized swelling of the submandibular salivary gland is apparent with probable ductal dilatation in the affected gland parenchyma.

The subsequent ultrasound at Freeman Hospital utilized the eL18-4 PureWave linear array with 3.5 cm depth, similar focal zone, but general mode setting (bottom, right). The submandibular salivary abnormality has decreased and a diagnosis of focal sialadenitis (salivary inflammation) was made from the external ultrasound images and clinical course. However, a low reflectivity abnormality was appreciated deep to the submandibular gland, within the left side of the oropharynx.



The Philips eL18-4 PureWave linear array transducer is our first high-performance transducer featuring ultra-broadband PureWave crystal technology with multi-row array configuration, allowing for fine-elevation focusing capability.

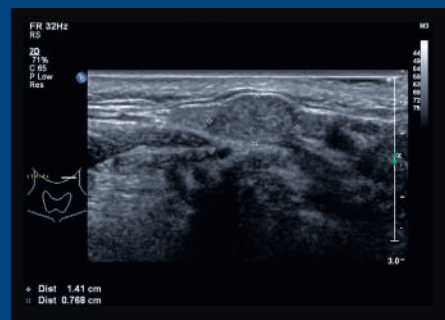
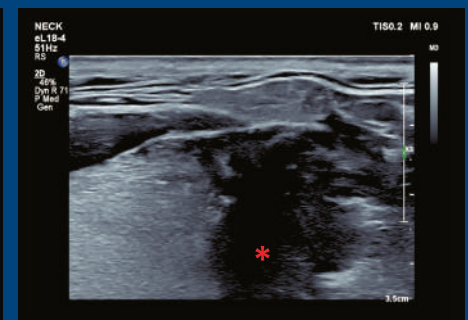
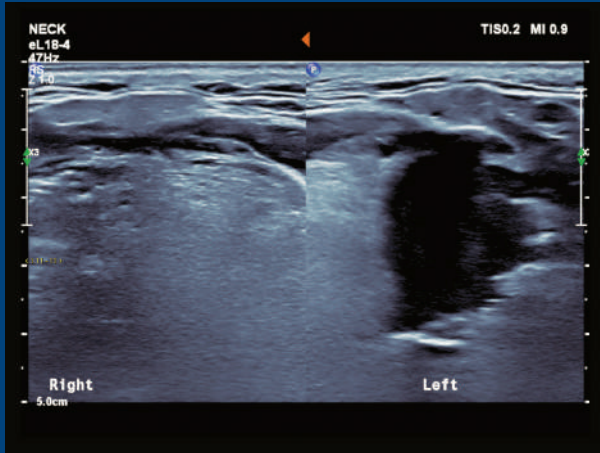


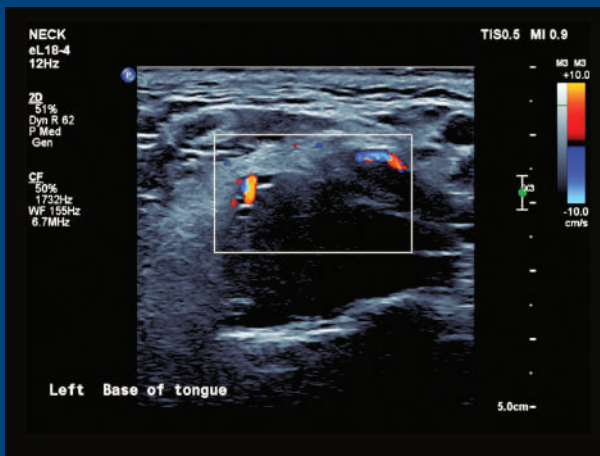
Image from external trust examination demonstrating focal lesion within the left submandibular gland.



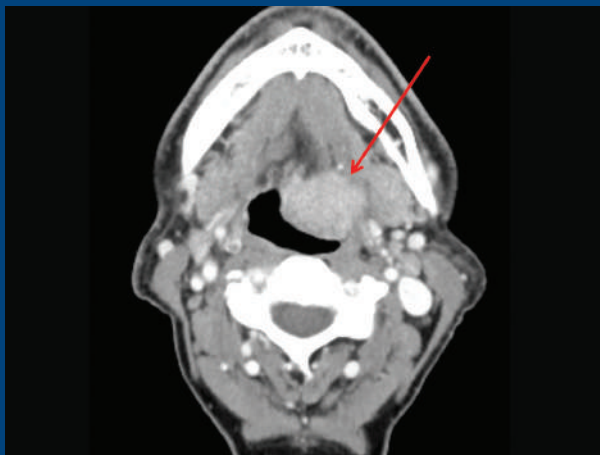Demonstrating the left submandibular gland, but with increased penetration, also demonstrating the deeper lesion within the left base of tongue (red asterisk).



Comparison view of the base of tongue in transverse on the right and left side.



Demonstrating relationship between mass in left base of tongue and the lingual artery.



Confirmation of margins and staging by CT shows the enhancing base of tongue mass (red arrow).

Findings

Transverse views obtained from a position immediately cranial to the hyoid bone demonstrated a 3.5 cm mass within the left side of the tongue base (left, top) and lymphoid tissue with delineation of the lingual artery at the deep margin of the mass using the same probe settings (left, center).

In light of these findings, flexible nasendoscopic examination was performed in the outpatient clinic with visual confirmation of an exophytic tongue base mass. A contrast-enhanced CT of the neck confirmed an enhancing soft tissue mass in the left oropharynx (left, bottom), with no regional lymphadenopathy or distant metastasis. Subsequent panendoscopy and biopsy under general anesthesia revealed a large lymphangioma (benign lymphovascular malformation).

Conclusion

Linear array transducers offer high-resolution anatomic assessment of neck anatomy, but traditionally have been limited to superficial structures only. Deeper neck structures have required use of separate, lower frequency transducers, with resulting limitations in spatial resolution. Using the eL18-4 PureWave linear array transducer, we were able to detect and delineate a pharyngeal (deep) neck space abnormality that was clinically occult in a symptomatic patient, despite using standard neck ultrasound settings with a focal zone optimized for superficial (common) pathology.

This unusual case highlights the clinical benefits of an improved combination of penetration and resolution within a single linear array transducer. Wider clinical applications include detection of occult neoplasia within the oropharynx, supraglottic larynx, and cervical oesophagus in patients who present with cervical lymphadenopathy, as well as benefits in non-head and -neck applications such as musculoskeletal and small parts examinations.

Reference

1 Tessler FN, MD, CM; Hammers LW, DO; et al. ACR Thyroid Imaging, Reporting and Data System (TI-RADS): White Paper of the ACR TI-RADS Committee. JACR 2017.

Results from case studies are not predictive of results in other cases. Results in other cases may vary.